

Painless palpable scrotal mass

Charis Anastasiadis, Georgia Kyriakopoulou, Charikleia Triantopoulou

Radiology Department, Konstantopoulou General Hospital of Nea Ionia, Athens, Greece

SUBMISSION: 9/7/2017 | ACCEPTANCE: 16/11/2017

PART A

An 87-year-old man with dementia was referred to the orthopaedic clinic of our hospital, suffering from spinal symptoms. Clinical examination revealed swelling of the left hemiscrotum and a painless ipsilateral palpable scrotal mass, which was attributed to a possible inguinal

hernia. The patient, who was unable to provide details regarding the time of appearance of the mass, subsequently underwent an ultrasound scan of the scrotum (**Figs. 1-3**). Based on the imaging findings surgical excision was decided (**Fig. 4**).



CORRESPONDING AUTHOR, GUARANTOR

Corresponding Author: Charis Anastasiadis
Radiology Department, Konstantopoulou General Hospital of Nea Ionia, 3-5 Agias Olgas str, 14233 N. Ionia, Athens, Greece, E-mail: anastcharis@hotmail.com
Guarantor: Charikleia Triantopoulou
Head of Radiology Department, Konstantopoulou General Hospital of Nea Ionia, E-mail: ctriantopoulou@gmail.com

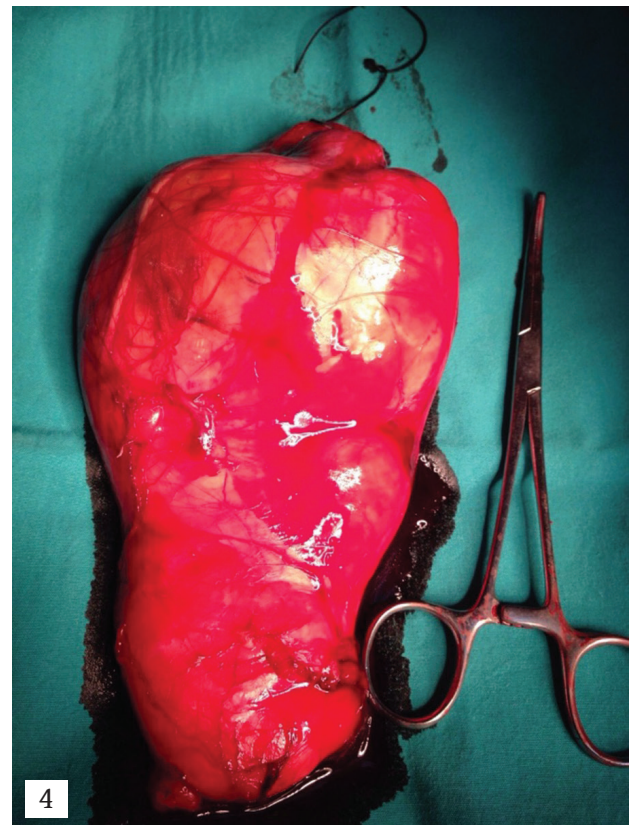
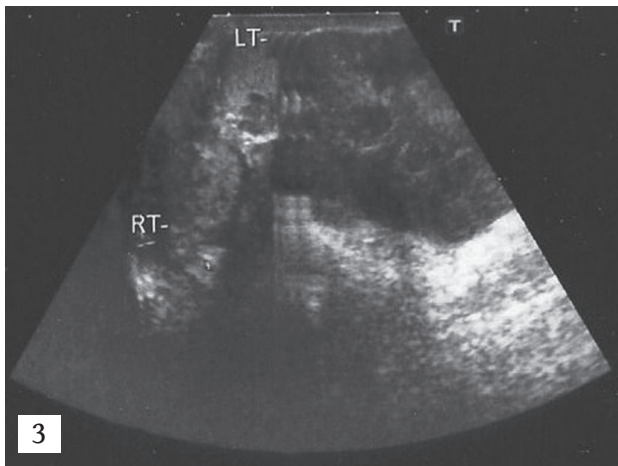
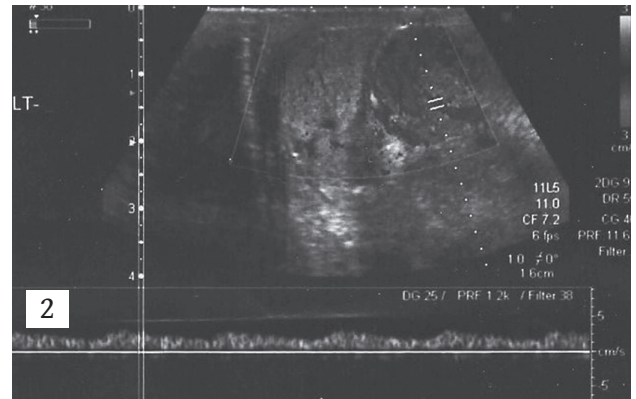
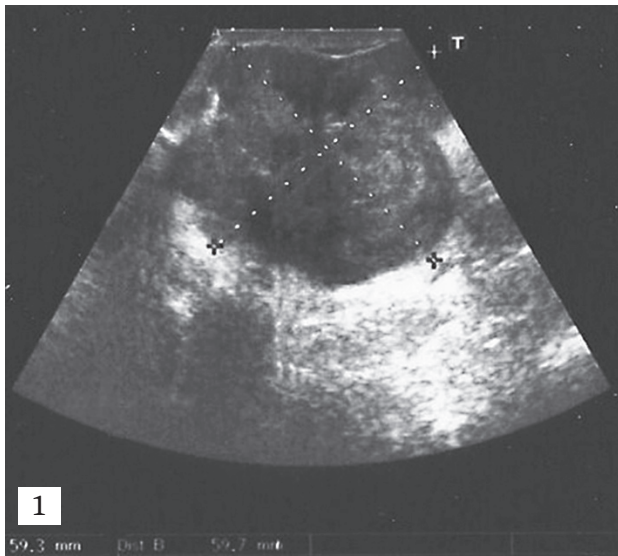


Fig. 1. B-mode ultrasound image of the scrotum. (oblique plane).

Fig. 2. Triplex ultrasound image of the scrotum. (sagittal plane).

Fig. 3. B-mode ultrasound image of the scrotum. (axial plane).

Fig. 4. Surgical specimen.

PART B

Diagnosis: Liposarcoma of the scrotum

Liposarcomas are malignant tumours of the fat tissue that arise from mesenchymal cells [1]. In almost 70% of cases, liposarcomas are detected in the extremities or the retroperitoneum [1]. Sarcomas of the genitourinary tract account for approximately 2% of soft tissue sarcomas [2].

Malignancies of the spermatic cord are considered relatively rare. Approximately 200 cases have been reported in the literature [1]. Spermatic cord liposarcoma is an entity which represents around 7% of all paratesticular sarcomas [1]. There are five histological subtypes of liposarcomas, which are closely related to clinical behaviour: well-differentiated, dedifferentiated, myxoid, round cell and pleomorphic [2, 3]. The most frequent histological subtypes of spermatic cord malignant tumours are: paratesticular liposarcoma (20-56%), leiomyosarcoma (19-32%) and rhabdomyosarcoma (11-24%) [3-5].

Liposarcoma is a tumour usually found in middle-aged patients and the average age at presentation is 55 years [6]. It can remain asymptomatic for a long period of time, but may potentially lead to life-threatening complications [1]. Clinical diagnosis is in most cases difficult and equivocal. Differential diagnosis of liposarcoma of the spermatic cord should include other paratesticular masses, such as inguinal hernia, hydrocoele, benign tumours (lipoma, leiomyoma, haemangioma) as well as malignant tumours (rhabdomyosarcoma etc.) [1].

In general, liposarcomas have a favourable prognosis because of their low malignant potential and relapses tend to be local. A high 5-year survival rate has been reported. [7]. Treatment is mainly surgical. Radical orchiectomy with wide local excision is currently thought to be the treatment of choice [1]. Among all types of sarcomas, liposarcomas are the most sensitive to radiation therapy. In two prospective randomised studies among patients with soft tissue sarcomas, it was shown that the combination of radiation therapy with surgical excision significantly reduces the likelihood of local recurrence [8].

Adjuvant radiation therapy is recommended in those cases where it is thought to have an extra positive effect for the patient, when there is local relapse or when there are bad prognostic factors [1]. In general, these malignancies are characterised by a significant frequency of local relapse and long-term follow-up of 10-20 years is recommended [1].

Ultrasonography has a sensitivity of 95-100% for distinguishing extratesticular from intratesticular lesions [2]. Paratesticular sarcomas usually have a heterogeneous pattern and are seen as hypervascular tumours on Doppler ultrasonography [9]. The presence of variable amounts of fat is a constant finding of liposarcomas. The amount of fat will determine the echogenicity of the tumour: the higher the amount of fat, the lower the echogenicity pattern of the tumour. However, US findings are often non-specific. MRI imaging is advantageous in assessing the presence of fat, better characterising and delineating the extension of the tumour and distinguishing extratesticular from testicular pathologic processes. Furthermore, MRI is preferable for staging and tumour aggressiveness assessment [2, 9].

Our patient had an ultrasound scan of the scrotum, which revealed a left hemiscrotum lobulated hypervascular paratesticular mass of mixed echogenicity, 6 cm in diameter, causing pressure and dislocation of the ipsilateral testis, which had a slightly heterogeneous echo-pattern (Figs. 1-3). The ultrasound scan of the right testis was unremarkable. A small right hydrocoele and bilateral scrotal oedema were also detected. The diagnosis of left paratesticular sarcoma was proposed and discussed based on US findings.

CT scan of the abdomen and chest followed for staging and the findings were negative. Moreover, the patient underwent an MRI scan of the spine as part of his lower back pain workup.

The patient was referred to the urology clinic and was scheduled for surgery. He underwent a left orchiectomy with wide local excision of the lesion. The histopathology department received a surgical specimen of 17 x 10 x 6.5 cm in size (Fig. 4). Histopathologic examination showed growth, within the spermatic cord, of a malignant neoplasm of mesenchymal origin, with morphological features of dedifferentiated liposarcoma. The dedifferentiated element of the tumour appeared to be a sarcoma of high-grade malignancy, comprising of sharply atypical spindle-like cells with high mitotic rate. Microscopically, regions of well-differentiated liposarcoma were also visible. The excised testis was not infiltrated by the sarcoma. **R**

Conflict of interest

The authors declared no conflicts of interest.

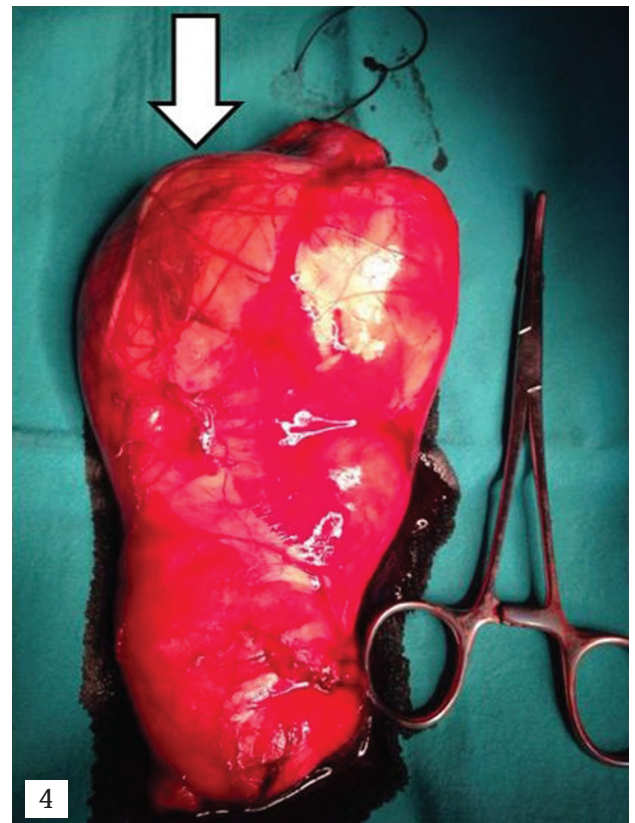
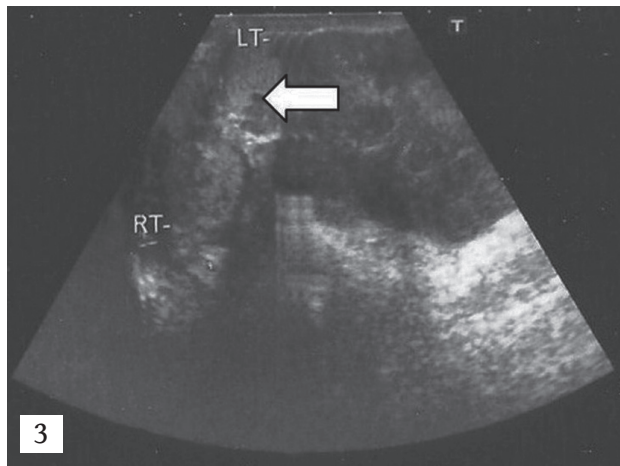
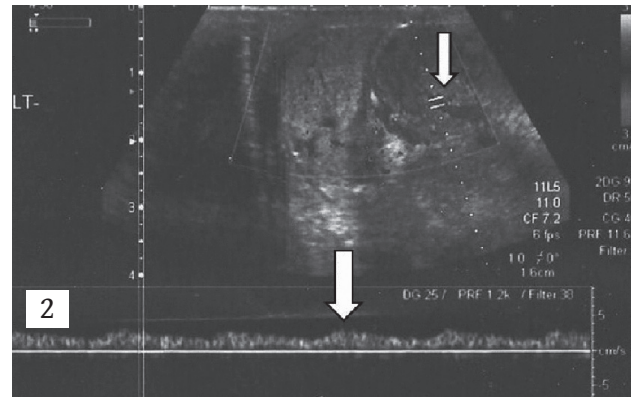
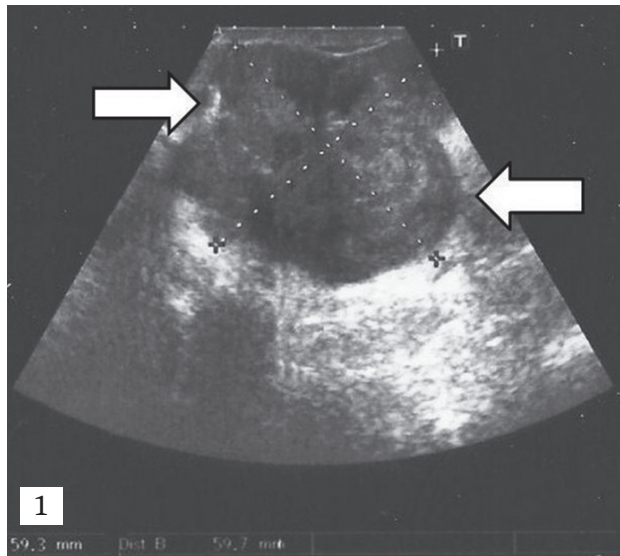


Fig. 1. B-mode ultrasound image of the scrotum (oblique plane). Lobulated left paratesticular mass with mixed echogenicity pattern, measuring 6 cm in diameter (between arrows).

Fig. 2. Triplex ultrasound image of the scrotum (sagittal plane). The mass (upper arrow) in the left hemiscrotum appears hypervascular. Spectral Doppler analysis reveals continuous waveform (lower arrow).

Fig. 3. B-mode ultrasound image of the scrotum (axial plane). The left paratesticular mass causes displacement of the ipsilateral testis (arrow), which appears with a slightly heterogeneous echo-pattern. LT: left testis, RT: right testis.

Fig. 4. Surgical specimen measuring 17 x 10 x 6.5 cm in size, including testis, epididymis, spermatic cord and a yellowish, white-brownish solid tumour (arrow).



KEY WORDS

Spermatic cord liposarcoma; paratesticular mass; ultrasonography of the scrotum

REFERENCES

1. Di Gregorio M, D'Hondt L, Lorge F, et al. Liposarcoma of the spermatic cord: An infrequent pathology. *Case Rep Oncol* 2017; 10: 136-142.
2. Panus A, Mesina C, Plesea IE, et al. Paratesticular liposarcoma of the spermatic cord: A case report and review of the literature. *Rom J Morphol Embryol* 2015; 56(3): 1153-1157.
3. Khoubehi B, Mishra V, Ali M, et al. Adult paratesticular tumours. *Br J Urol Int* 2002; 90(7): 707-715.
4. Mondaini N, Palli D, Saieva C, et al. Clinical characteristics and overall survival in genitourinary sarcomas treated with curative intent: A multicenter study. *Eur Urol* 2005; 47(4): 468-473.
5. Dotan ZA, Tal R, Golijanin D, et al. Adult genitourinary sarcoma: The 25-year Memorial Sloan-Kettering experience. *J Urol* 2006; 176(5): 2033-2038.
6. Yoshino T, Yoneda K, Shirane T. First report of liposarcoma of spermatic cord after radical prostatectomy for prostate cancer. *Anticancer Res* 2009; 29: 677-680.
7. Lee HN, Kim MS. Liposarcoma of the testis and spermatic cord. *Open J Urol* 2013; 3: 68-70.
8. Yang JC, Chang AE, Baker AR, et al. Randomized prospective study of the benefit of adjuvant radiation therapy in the treatment of soft tissue sarcomas of the extremity. *J Clin Oncol* 1998; 16: 197-203.
9. Akbar SA, Sayyed TA, Jafri SZ, et al. Multimodality imaging of paratesticular neoplasms and their rare mimics. *Radiographics* 2003; 23(6): 1461-1476.

READY - MADE
CITATION

Anastasiadis C, Kyriakopoulou G, Triantopoulou C. Painless palpable scrotal mass. *Hell J Radiol* 2018; 3(1): 66-70.